

‘Aesthetic shaping of the neck/positive *side effects on the gingiva*’

Warren Roberts, DMD

This article discusses the relationship between Platysma, a large muscle of the face and neck, and the periodontium of the lower teeth. The article explores the relationship between the contraction of the platysma muscle during its repeated use as a muscle of facial expression, the pull of labial mandibular frenums and the development of gingival recession. The use of Botox Cosmetic to soften the action of this muscle is suggested as a minimally invasive therapy in preventing gingival recession.

It is now widely recognized that there is a critical relationship between the muscles of facial expression, facial soft tissue contours and dental smile design ⁽¹⁾. Among other factors, the amount of upper incisor display is influenced by the volume of the cheeks, the fullness of the lips and even the activity of muscles in the glabellar region. All the muscles of facial expression are interconnected ⁽²⁾. The aging soft tissue of the face must be included in the diagnosis prior to definitive cosmetic dental treatment as the final restorative approach needs to take into account other facial esthetic treatments that many patients undertake. Is it possible that other muscles of facial expression also exert a dental influence, specifically the “aging” of the periodontium? With age occurs gingival recession, loss of attached gingiva and exposed root surfaces (Fig. 1). These conditions pose an

ongoing maintenance problem as well as contributing to tooth loss. Traditionally gingival recession has been attributed to aggressive tooth brushing or flossing, untreated periodontal disease, occlusal dysfunction, abfraction, genetics and age. There may be another factor that has been overlooked. Current treatment for lack of gingival attachment often involves surgical intervention through various grafting procedures (Fig. 2 & 3). Subsequently, the frenums are often still observable exerting a downward pull (Fig. 4). Which muscles contribute to this force both before and after periodontal surgery (Fig. 5 & 6a,b,c)? Could these muscles be a major factor in the development and progression of gingival recession? Do we now have a way of decreasing the undesirable action of these muscles in the periodontium?

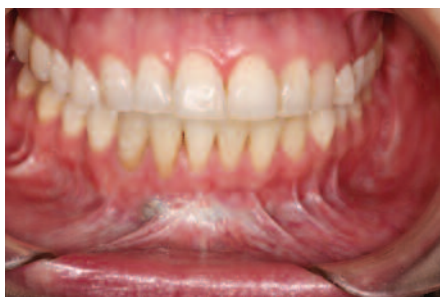

Figure 1: The aging periodontium with gingival recession, loss of attached gingiva & exposed root surface

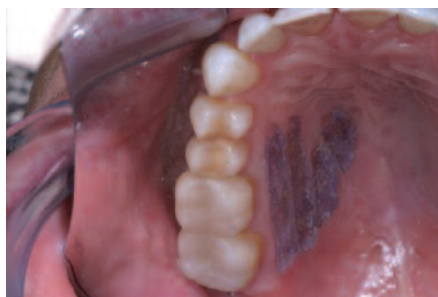

Figure 2: Maxillary palate donor site for free gingival tissue graft

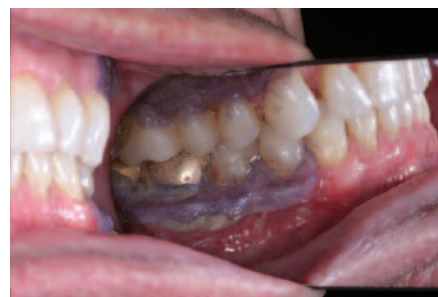

Figure 3: Surgical repair of attached gingiva & recession

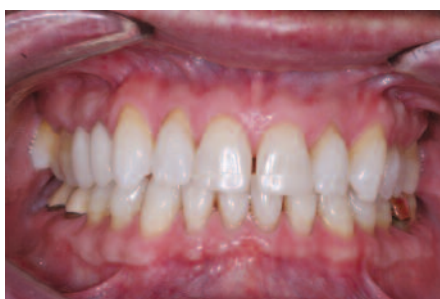

Figure 4: Post-op site-with increased attached gingiva- the frenums are still active

The orbicularis oris muscle surrounds the oral aperture. It has no bony origin and is suspended in space by muscles radiating from it in all directions. There are various muscles that pull the corners of the mouth inferiorly---depressor anguli oris, depressor labii inferioris, mentalis and platysma (Fig. 5) Platysma (Fig. 6a,b,c) is a large, broad sheet of muscle that arises from the fascia covering the upper parts of the pectoralis major and deltoid. Its fibers cross the clavicle and proceed obliquely upward and medially along the side of the neck. The anterior fibers, Platysma Mandibularis (Fig. 6a) interface below and behind the mental symphysis with fibers of the muscle of the opposite side. Its middle fibers, Platysma Labialis (Fig. 6b) cross the mandible, some inserting into the bone below the oblique ridge, others into the skin of the subcutaneous tissue of the lower part of the face and frenums. The posterior fibers, Platysma Modiolaris (Fig. 6c) blend with the muscles about the angle and lower part of the mouth, the modiolus. The anterior portion is the thickest part of the muscle and depresses the jaw and draws down the lower lip and angle of the mouth in the expression of melancholy. When all the fibers of Platysma work together, it increases the diameter of the neck as seen during intense breathing after fast running. Platysma muscle bands can become thick and cordlike as we age. Activation of the platysma muscle can present clinically as strong vertical bands extending from its origin near the clavicle to the angle of the mouth. Commonly there are four vertical bands

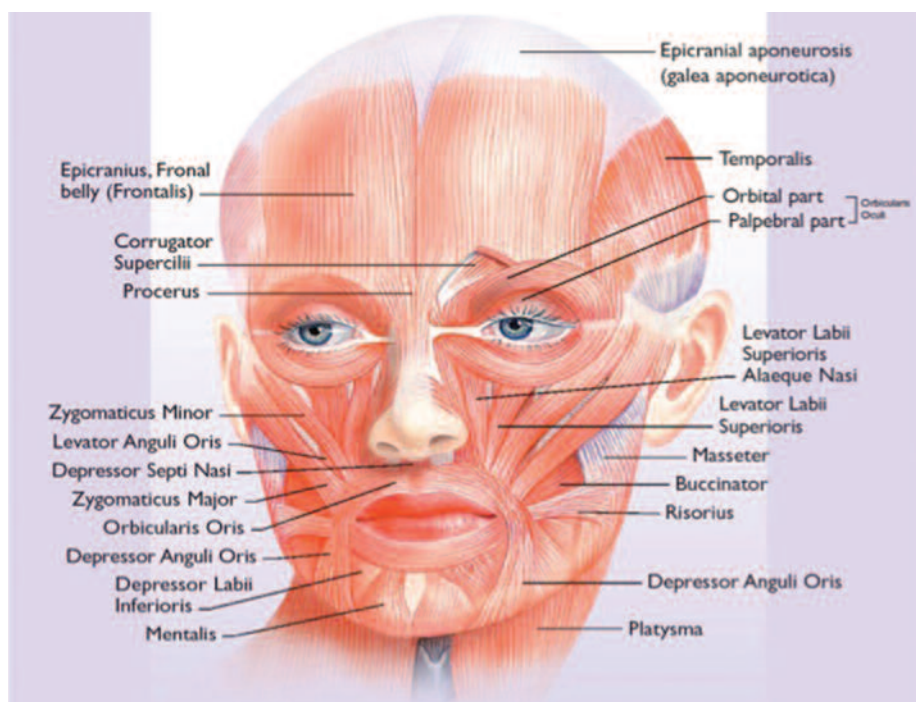


Figure 5: Muscles of the face

(Fig.7, 8 & 9). The left & right anterior vertical bands are related to the development of the anterior jowl (the fold of loose flesh under the lower jaw that develops as we age). The left & right lateral vertical bands are related to the downward pull of the angle of the mouth and the lateral jowl (Fig.10 & 11). With age there is greater platysma banding and an increase in the diameter of the neck and jowl development in the lower face through repeated use of the muscle (Fig.12 &13).

Photography is essential in evaluating the action of muscles and their influence on the face and neck⁽³⁾. As esthetic dentists that also incorporate facial esthetic treatments into our dental practice we use photography daily as part of our diagnosis, treatment planning and follow up procedures. We soon realized that the status of current medical photography was not adequate for our needs. We developed a series of photographs that when combined with the standard cosmetic dental photography (such as the series taught by the AACD) allowed much more information to be obtained. The Roberts

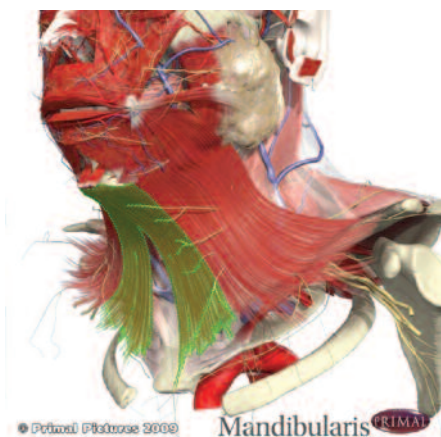

Figure 6a: Frontalis Mandibularis

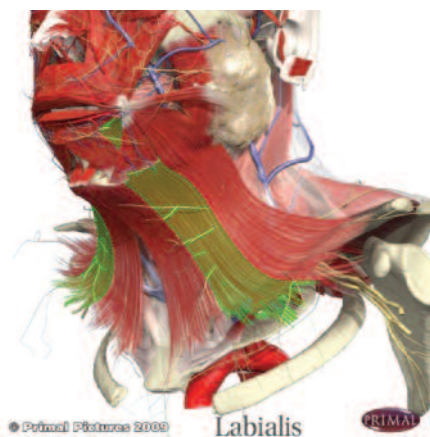


Figure 6b: Frontalis Labialis

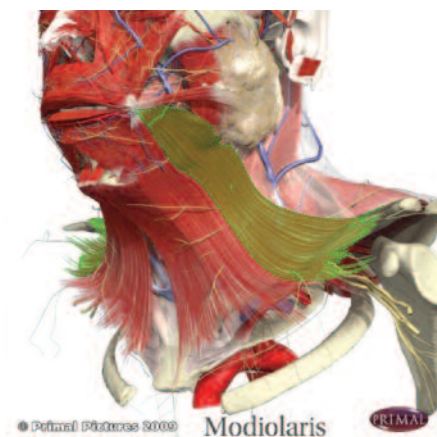


Figure 6c: Frontalis Modiolaris

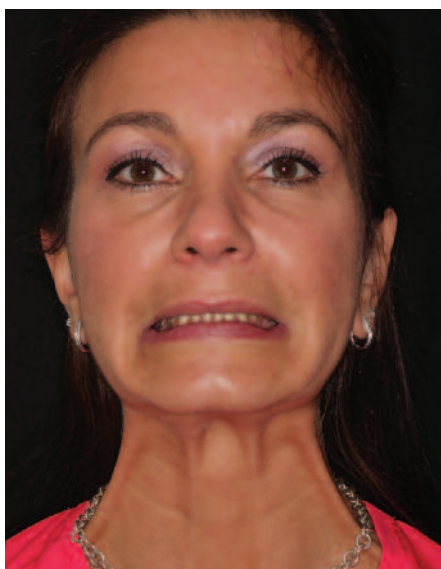

Figure 7: Full face frontal active showing the two anterior & two posterior vertical platysma bands

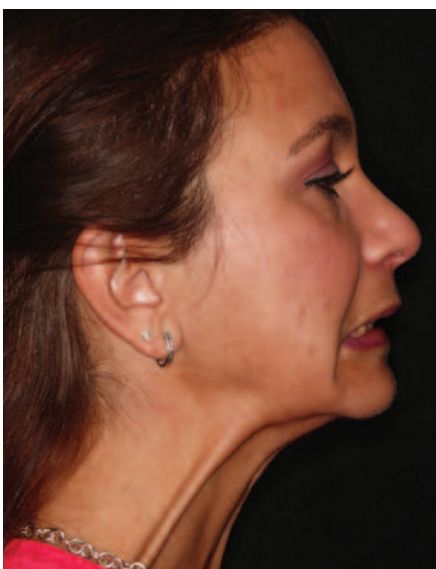

Figure 8: Sagittal right active showing the anterior & posterior vertical platysma bands

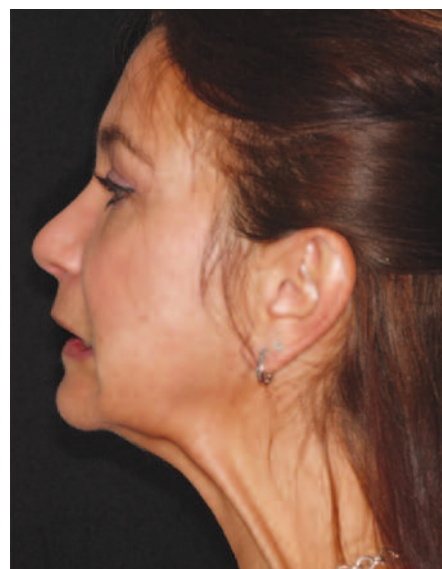

Figure 9: Sagittal left active showing the anterior & posterior left vertical platysma bands

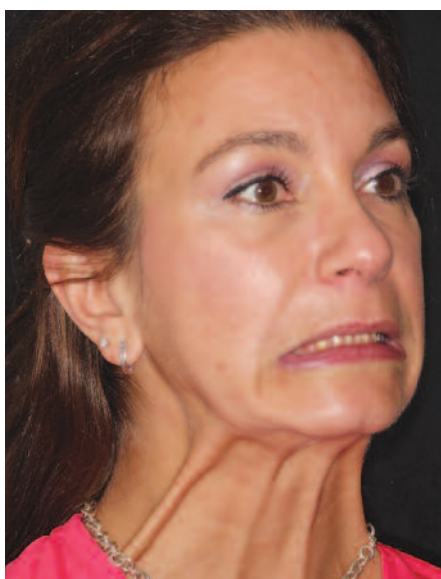

Figure 10: 45 degree right active showing the two anterior & two posterior vertical platysma bands



Figure 11: 45 degree left active showing the two anterior & two posterior vertical platysma bands



Figure 12: Only smiling- showing the increase in the diameter of the neck & jowl development with age

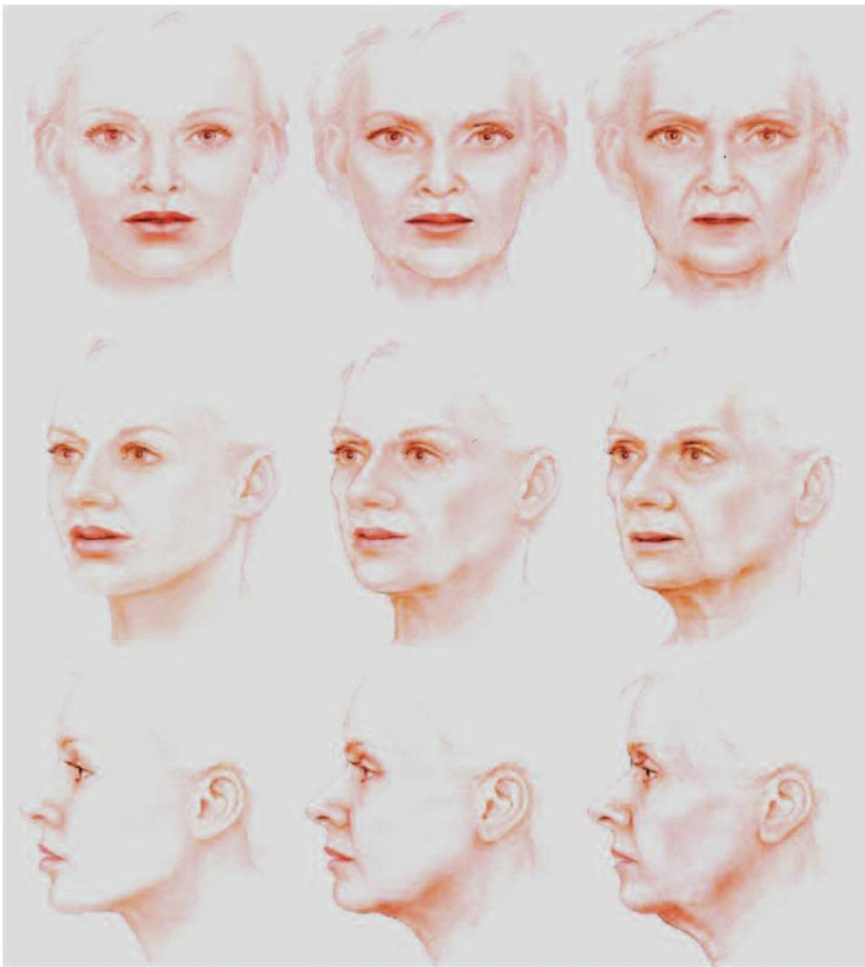


Figure 13: Artist conception of the Facial Aging process by Coleman

Facial Rejuvenation Photography series (RFRP) comprises 28 facial photographs and 1 intra-oral photograph to assist in overall facial aesthetic diagnosis and treatment planning (Fig 14). Both the patient and the treating dentist are able to view the face from various angles in the relaxed state and also when the muscles of facial expression are activated (Fig 15). The RFRP series assists in evaluating muscle size, strength and position relative to the aging process. After reviewing the RFRP series of many patients we have observed that the platysma bands are frequently asymmetrical in their pull (Fig.16 & 17) evidenced facially by the appearance of a jowl primarily on one side (Fig.18 & 19). Furthermore, we found that those patients exhibiting unilateral platysma bands often also exhibited unilateral gingival recession. This occurs in all age groups from younger patients with virgin teeth (Fig.20-22), to older individuals (Fig.24-26). Further review showed a marked correlation between the strength of the platysma band and gingival recession in many patients. This observation has led to the hypothesis that the strong influence of platysma contributes to gingival recession, particularly those with a genetic



Figure 14: Roberts Facial Rejuvenation Photography (RFRP) series 28 facial & 1 intraoral



Figure 15: Patient viewing the RFRP series On the monitor & highlighting on their own photograph areas of concern



Figure 16: Full face frontal relaxed with canted mouth to right & necklace lines



Figure 17: Full face frontal active with unilateral right Platysma bands involved in cant

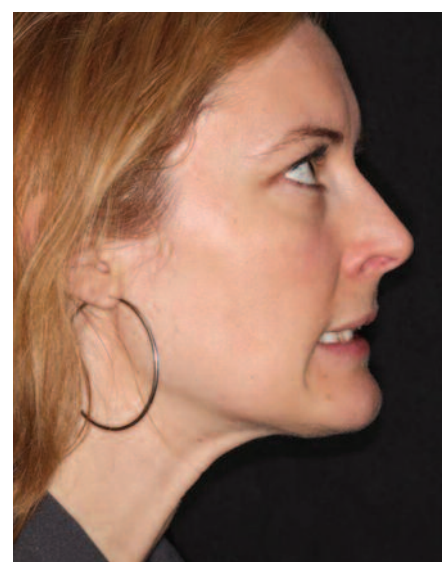

Figure 18: Sagital right active with right unilateral Platysma

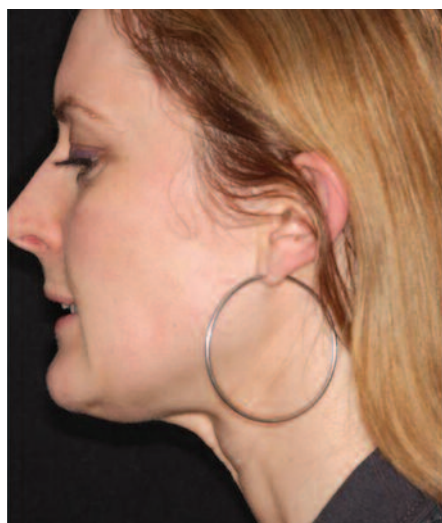

Figure 19: Sagital left active with no left platysma band-note the lack of left jawl

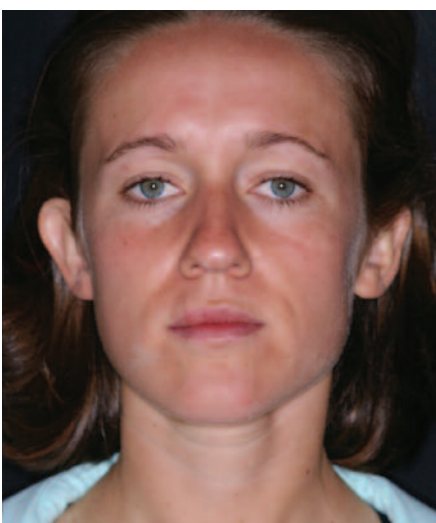

Figure 20: Younger patient full face frontal relaxed with canted mouth to right with necklace lines

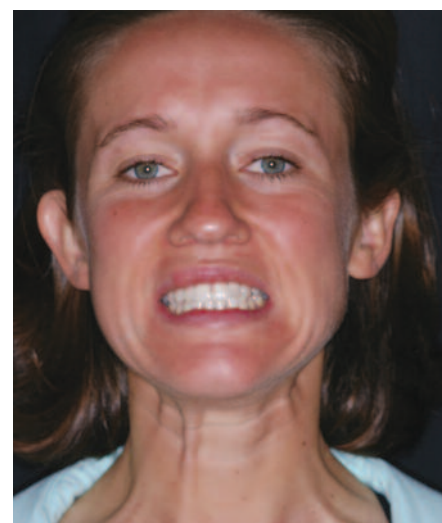

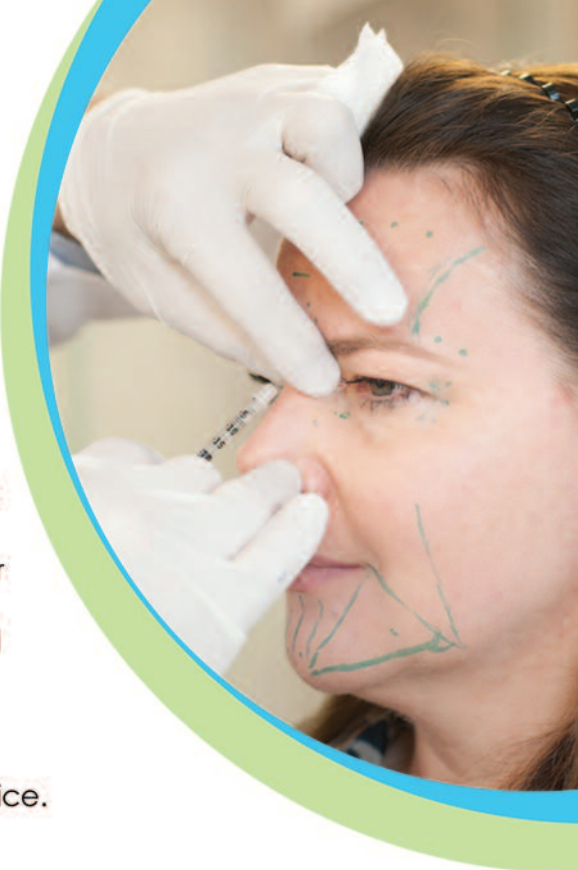Figure 21: Younger patient full face active unilateral right platysma bands involved in cant

BOTOX® for the MODERN DENTAL PRACTICE

Join some of the most highly trained Botox® and facial rejuvenation providers.

The Pacific Training Institute for Facial Aesthetics offers an advanced anatomy-based training program known for its high caliber of teaching and patient care practices. For dentists who are looking for the best in class facial rejuvenation program, we are the only educational provider that offers an unprecedented depth of clinical teaching and whose educational model has been adopted by regulatory boards to help develop the standard of practice.

Confidently and successfully integrate Botox® into your dental practice.



THE PTIFA TRAINING ADVANTAGE:

- **Online Course:** Start today with the online L1A course (12 CE).
- **Hands-On & e-Cadaver:** Attend a hands-on cadaver program and gain access to online e-cadaver videos - great for reviewing anatomy in the future.
- **Team Training:** Complete practice integration and success with our extensive two-day hands-on training for the entire dental team.
- **Photography:** Learn the Roberts Facial Rejuvenation Photography™ series - a fast and effective system for assessment & to achieve 99% case acceptance.
- **Online Study Club:** Case support back in practice with Dr. Roberts with our online Botox® Study Club.
- **Marking & Injection Templates:** Learn the PTIFA marking & injection technique and achieve predictable and desired results.

START TODAY WITH THE ONLINE LEVEL 1A COURSE.

SAVE \$200 WITH "**TEAMWORKS**" PROMO CODE (EXPIRES JULY 31, 2015). VISIT PTIFA.COM



PACIFIC
TRAINING
INSTITUTE
for FACIAL AESTHETICS



Dr. Warren Roberts is a leading Botox® educator whose Vancouver clinic is the number one administrator of Botox® across North American dental practices. Since 2008, he has trained over 7,000 doctors nationally and internationally, and has treated hundreds of Botox® patients.



ADA+C Approved

ADA C-E-R-P® | Continuing Education
Recognition Program

VISIT PTIFA.COM OR CALL 1-855-681-0066

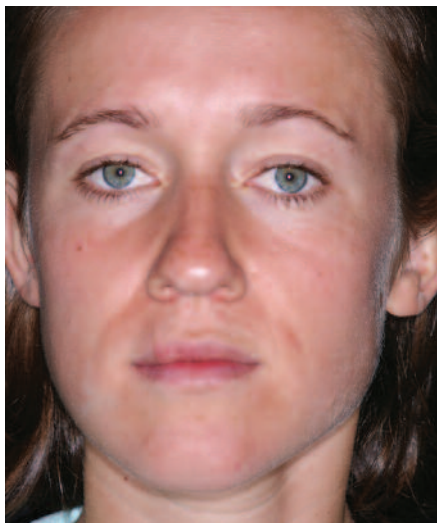

Figure 22: Close up face canted mouth down on the right-note the indentation on the left neck

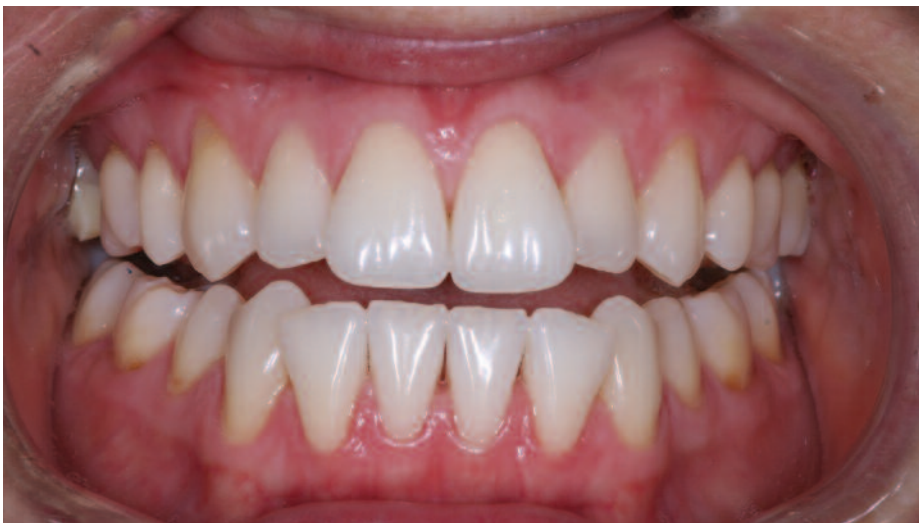

Figure 23: Younger patient with unilateral right platysma associated with more recession on same right side



Figure 24: Older patient full face frontal relaxed



Figure 25: Older patient full face frontal active with right unilateral anterior platysma band

risk factor for recession. If one strongly activates one's own platysma muscles, it is easy to feel this large muscle's pull intra-orally. Using the RFRP series, intra-oral photography and periodontal charting it is possible to document the association of gingival recession and the inferior pull of platysma.

Botox Cosmetic is used extensively and safely to decrease the action of the muscles of facial expression and soften the appearance of the face and neck. It is frequently used to decrease the strength of the platysma muscle and its

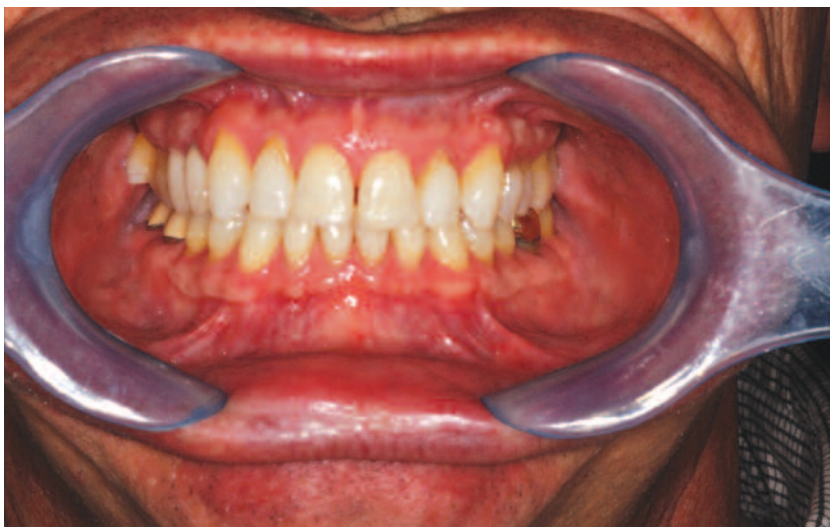

Figure 26: Older patient with unilateral right Platysma with more aggressive right gingival graft




Figure 27: Full face frontal active with large neck



Figure 28: Full face frontal active 4 weeks (mid treatment) showing reduced activity & neck size

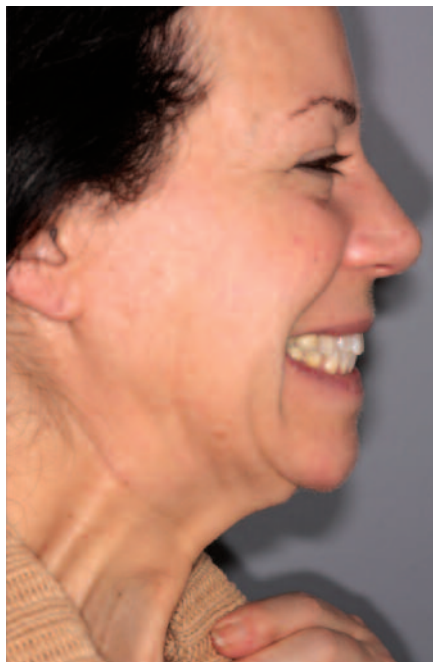


Figure 29: Sagittal right active with large neck



Figure 30: Sagittal right 4 weeks (mid treatment) showing reduced activity & neck size

inferior pull, minimizing the development of the jowls on the sides of the face and the appearance of “necklace lines” around the neck. Apart from the positive esthetic effect this treatment has on the neck (Fig:27-37), Botox therapy may also prove to have a significant therapeutic effect in preventing gingival recession in the mandible. Could softening the action of this large muscle that exerts a strong downward pull adjacent to delicate gingival tissues improve periodontal health by reducing gingival recession and loss of gingival

attachment? The evidence strongly points in this direction. Further research is needed to determine if Botox Cosmetic can be used preventatively as a minimally invasive treatment for gingival recession and to reduce the need for surgical intervention.

There are currently few FDA approved uses for Botox. Our medical colleagues have ventured outward and there are now hundreds of off label uses for Botox. These include treating infants to assisting the elderly cope with daily routines.



WE PROVIDE ALL YOU NEED IN DIGITAL

Palmeri Media Group

Specializes in Dental websites

- ▶ Website creation
- ▶ Digital reprints
- ▶ Targeted Email marketing
- ▶ Digital editions

- ▶ Digital news letters delivery
- ▶ Digital data
- ▶ Email blast
- ▶ Website hosting

For information contact Samira at 905.489.1970 Ext. 212 or email samira@palmeripublishing.com

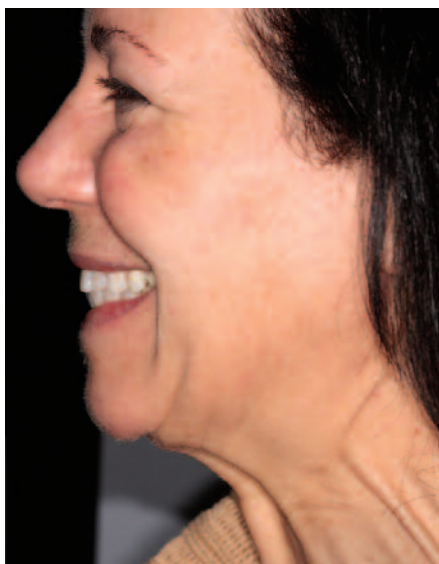

Figure 31: Sagittal left active with large neck



Figure 32: Sagittal left active 4 weeks (mid treatment) showing reduced activity & neck size



Figure 33: 45 degree left active with large neck



Figure 34: 45 degree left active 4 weeks (mid treatment) showing reduced activity & neck size



Figure 35: 45 degree right active with large neck




Figure 36: 45 degree right active 4 weeks (mid treatment) showing reduced activity & neck size



Figure 37: Full face frontal relaxed, A pleased patient 4 weeks (mid treatment) showing reduced neck size

It is time for the dental profession and our research facilities to begin to explore ways to utilize the therapeutic and cosmetic benefits of the medication.

In our next article we would like to explore the cosmetic use with the benefits to the periodontium. ■

References:

- (1) Roberts, J & W Incorporating Facial Rejuvenation into the Dental Practice Teamwork 2015 Vol.8 No.1: 52-61
- (2) Friedman, S.M. Visual Anatomy I Head & Neck 1970:55
- (3) Roberts, J. & W. Botox and Photography Teamwork 2015; Vol.8 No.2: 50-62



Dr. Warren Roberts is the Clinical Director for the Pacific Training Institute for Facial Aesthetics (PTIFA) and is a leading Botox educator whose Vancouver clinic is the #1 administrator of Botox across North America dental practices. He is the developer of the Roberts Facial Rejuvenation Photography series, the PTIFA Cosmetic & Therapeutic Marking Templates, the PTIFA injection technique and established the first online Botox Study Club. He can be reached at drwarren@ptifa.com or 1-855-681-0066.